

Glove Tears During Arthroscopic Shoulder Surgery Using Solid-Core Suture

Kevin M. Kaplan, M.D., Konrad I. Gruson, M.D., Chris T. Gorczynski, M.D.,
Eric J. Strauss, M.D., Fred J. Kummer, Ph.D., and Andrew S. Rokito, M.D.

Purpose: Surgeons have noticed an increased incidence of finger lacerations associated with arthroscopic knot tying with solid-core suture material. This study examines glove perforations and finger lacerations during arthroscopic shoulder surgery. **Methods:** We collected 400 surgical gloves from 50 consecutive arthroscopic shoulder repair procedures using No. 2 solid-core sutures. Two surgeons using double gloves were involved in every case, with one being responsible for tying all knots. Powder-free latex gloves were worn in all cases. Knots consisted of a sliding stitch of the surgeon's preference followed by 3 half-hitches via a knot-pusher instrument. All gloves were inspected grossly and then tested for tears with an electroconductivity meter. **Results:** The knot-tying surgeon had significantly more glove tears than the control ($P < .01$). Tears were localized to the radial side of the index finger of the glove at the distal interphalangeal joint in all cases. Of the tying surgeon's gloves, 68 (34%) were found to have tears. These included 17 inner gloves (17%) and 51 outer gloves (51%). If an inner glove was torn, the corresponding outer glove was torn in all cases. A mean of 3.96 knots were tied in each case. There was a significantly higher incidence of inner glove tears when more than 3 knots were tied ($P < .03$). There was no significant difference in glove tears between suture types. Finger lacerations did occur in the absence of glove tears. However, in the presence of an inner glove tear, there was a statistically significant association with a finger laceration at the corresponding level ($P < .03$). **Conclusions:** Intraoperative glove tears and subsequent finger lacerations occur with a high frequency when arthroscopic knots are tied with solid-core suture material. Risk can potentially be minimized by frequent glove changes or use of more durable, less penetrable gloves. **Clinical Relevance:** This study addresses surgeon and patient safety during arthroscopic shoulder surgery. **Key Words:** Glove perforation—Finger laceration—Shoulder arthroscopy—Arthroscopic knot tying.

Orthopaedic surgeons operate on patients with infectious diseases, including human immunodeficiency virus (HIV), hepatitis B virus, and hepatitis C virus. With an increasing incidence of these diseases in the general population, the surgeon must adhere to strict universal precautions. In addition, the literature

has documented the exposure of operating room personnel to infectious material.¹⁻³ Although simple skin contamination carries a lower risk of seroconversion than inoculation injuries, skin contamination occurs frequently and minor cuts and skin abrasions eliminate the body's natural protective barrier.⁴ Thus, prevention and immediate recognition of glove perforation in the operating room are of paramount importance. The routine use of double gloves has been established as a means to protect both the patient and operating surgeon from a breach in sterility and transmission of potential pathogens.⁵ However, despite improved materials and the use of double gloves, perforations and finger lacerations occur during arthroscopic shoulder surgery.

Glove perforation during surgical procedures of any

From the New York University Hospital for Joint Diseases, New York, New York, U.S.A.

The authors report no conflict of interest.

Address correspondence and reprint requests to Kevin M. Kaplan, M.D., Department of Orthopaedic Surgery, NYU Hospital for Joint Diseases, 301 E 17th St, Suite 1402, New York, NY 10003, U.S.A. E-mail: kaplak02@med.nyu.edu

© 2007 by the Arthroscopy Association of North America

0749-8063/07/2301-6294\$32.00/0

doi:10.1016/j.arthro.2006.10.012

type has been reported to occur in 11% to 70% of cases.⁵⁻¹¹ Despite this high incidence, surgeons are aware of perforation only 15% of the time.^{12,13} Reports in the literature show that some of the highest rates of glove tears occur during bony fixation in orthopaedic surgery cases.^{10,14} Arthroscopic procedures, on the other hand, are less bloody and invasive than their open counterparts. Despite this, blood-tainted fluid routinely contacts surgeons' gloves during the procedure. Instrumentation, needles, bone and tissue allografts, and surgical equipment all have the potential to create glove tears, exposing both the operating surgeon and patient to potentially infectious material.¹⁵ Matava and Horgan¹⁶ reported on the presence of HIV in an arthroscopic effluent during a routine meniscectomy. Of 6 aliquots collected during the procedure, 2 contained HIV, thereby demonstrating a potential source of infection to the operating personnel.

With the advent of solid-core suture material, surgeons have anecdotally noted an increased incidence of finger lacerations associated with arthroscopic knot tying (Fig 1). Often, however, there is no gross evidence of glove penetration. Given the aforementioned concern regarding patient and surgeon safety in the operating room, this study evaluated glove tears and concomitant finger lacerations during arthroscopic surgery. Our hypothesis was that the surgeon exposed to the risk of knot tying would have a higher incidence of glove perforations and finger lacerations.

METHODS

We collected 400 surgical gloves from 50 consecutive arthroscopic shoulder repair procedures, including rotator cuff repairs and labral repairs, using No. 2

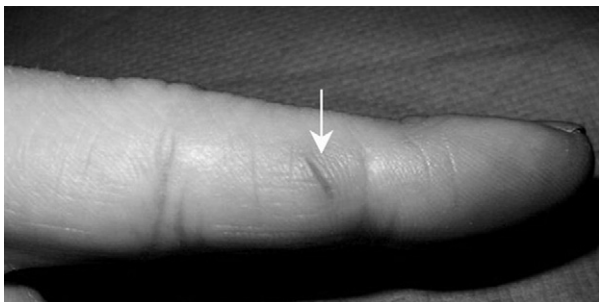


FIGURE 1. Finger laceration after arthroscopic knot tying (arrow). The level of this injury was just proximal to the distal interphalangeal joint. This case represented a tear of both the outer and inner gloves corresponding to the injured digit.

solid-core suture material. These cases involved fellowship-trained attending surgeons, fellows in sports medicine and shoulder or elbow surgery, and senior residents. FiberWire (Arthrex, Naples, FL) was used in 21 cases (42%), and Orthocord (DePuy Mitek, Raynham, MA) was used in 29 (58%). FiberWire is a blend of ultrahigh-molecular weight polyethylene multifilament core with a braided polyester jacket composed of a combination of ultrahigh-molecular weight polyethylene and polyester, which is then coated for use. Orthocord is a synthetic, sterile, braided, composite suture composed of dyed absorbable polydioxanone and nonabsorbable polyethylene, which is coated with a copolymer of 90% caprolactone and 10% glycolide. The choice of suture material for each case was based on attending surgeon preference.

Twenty-five pairs of unused powder-free latex gloves were used to validate our model. All gloves were presoaked in a normal saline solution bath. The gloves were then filled with normal saline solution and inspected for perforations. The gloves were completely immersed in the saline solution bath with one electrode inside the glove and one electrode in the bath (Fig 2A and 2B). No current was detected in all 50 gloves, indicating no laceration. A small cutting needle was then used to perforate the glove of the index finger, and the test was repeated. Current was detected in all 50 gloves (Fig 2C). The gloves were then dried, and individual digits were tested. The perforation was localized to the index finger in all 50 gloves.

Two surgeons using double gloves were involved in every case, with one being responsible for tying all knots and the other serving as a control. Powder-free latex gloves (Ansell, Dothan, AL) were worn in all cases. Surgeons replaced their outer gloves both after draping and before removal of the surgical drapes. For the purposes of this study, one knot was defined as an initial sliding stitch of the surgeon's preference, followed by 3 half-hitches via a single-hole knot-pusher instrument. At the end of the procedure, both sets of gloves were collected, and the type of surgery performed, suture material used, number of knots thrown, and presence, absence, and location of a finger laceration were recorded. If a glove was torn during the surgery, the surgeon was asked to save the glove and to submit all subsequent gloves used during the surgery. Surgeons were provided a data sheet to record the aforementioned information.

Postoperatively, the gloves were taken to the laboratory and inspected grossly after being filled with




FIGURE 2. Electroconductivity test. (A) Setup. (B) Negative test with intact glove. (C) Positive test with punctured glove (where the reading on the meter should be noted).

normal saline solution. They were then tested for tears via a previously validated protocol by use of an electroconductivity meter in a saline solution bath.^{17,18} Sohn et al.¹⁸ showed the increased sensitivity of the electrical conductance test when compared with the standard water load test in detecting artificially created glove tears. The setup for the testing apparatus is depicted in Fig 2A. If a positive test was obtained, defined as the presence of any electrical current, the glove was dried completely and each individual digit was tested. The examiners were blinded during the testing process.

The data were analyzed by use of the GraphPad INSTAT statistical package (version 3; GraphPad Software, San Diego, CA) to determine the incidence of glove perforation and finger lacerations occurring during arthroscopic shoulder procedures. Analyses were performed with a 2-sided Fisher exact test with statistical significance defined as $P < .05$.

RESULTS

When the outer gloves were analyzed, 9 of 100 gloves (9%) were torn in the non-tying control group

and 51 of 100 (51%) were torn in the tying group ($P < .0001$). The evaluation of the inner gloves showed that 2 of 100 gloves (2%) were torn in the non-tying control group and 17 of 100 (17%) were torn in the tying group ($P < .001$) (Fig 3).

With regard to the tying surgeon's gloves, tears were localized to the radial side of the index finger portion of the glove at the level of the distal interphalangeal joint in all cases. If an inner glove was torn, the corresponding outer glove was torn in 100% of cases. A mean of 3.96 knots was tied in each case. Greater than 3 knots were thrown in 32 cases, and 3 or fewer knots were thrown in 18 cases. No significant association was found between the number of knots thrown and tears in the outer glove ($P = .30$; for 80% power, 745 specimens would need to be tested). However, inner tears were seen in 15 of 49 gloves (31%) when greater than 3 knots were thrown and in 2 of 34 gloves (6%) when 3 or fewer knots were thrown ($P < .03$) (Fig 4). No significant difference in the number of glove tears was found between the two suture types in this study ($P = .45$; for 80% power, 1,274 specimens would need to be tested). In addition, in all cases in which a glove was removed during surgery for an obvious tear, none of the replacement outer gloves were noted to have a perforation in the laboratory.

Thirteen fresh finger lacerations were noted during the testing period. All lacerations were detected by the tying surgeon at the conclusion of the case. However, numerous surgeons reported a callus at

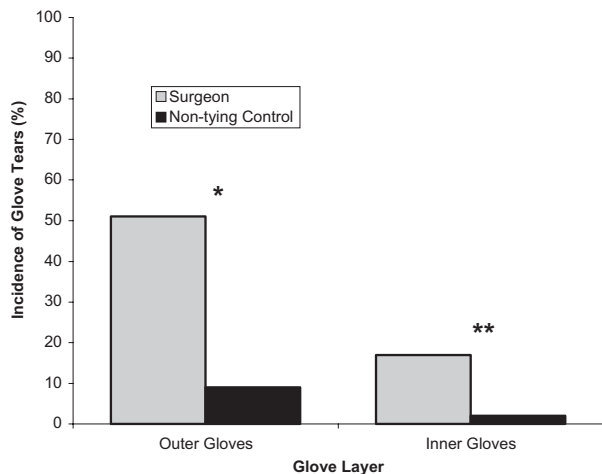


FIGURE 3. Incidence of outer and inner glove tears for tying surgeon and non-tying control. The difference for both the outer (1 asterisk, $P < .0001$) and inner (2 asterisks, $P < .001$) sets of gloves was found to be significant. The presence of glove tears in the control group is likely a result of handling of instruments in assisting the surgeon.

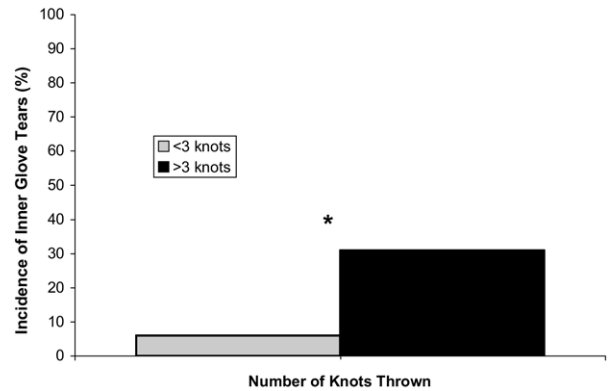


FIGURE 4. Incidence of inner glove tears versus number of suture knots thrown (as defined in text). In the setting of more than 3 knots thrown, there was a significantly increased incidence of inner glove tears for the tying surgeon (asterisk, $P < .03$).

the distal interphalangeal point from previous finger injuries, ostensibly from repeated suture trauma. Lacerations occurred in the absence of an inner glove tear in 7 of 83 cases (8%). However, in the presence of inner glove tears, fresh lacerations occurred in 6 of 17 cases (35%) ($P = .03$) (Fig 5). In addition, of the 13 finger lacerations, 6 were associated with an inner glove tear at the same level (46%).

DISCUSSION

Surgical gloves remain integral to patient and surgeon safety during operative arthroscopy. The literature has reported rates of glove perforation in orthopaedic procedures ranging between 26% and 57%.^{19,20} Fingertips become contaminated in approximately

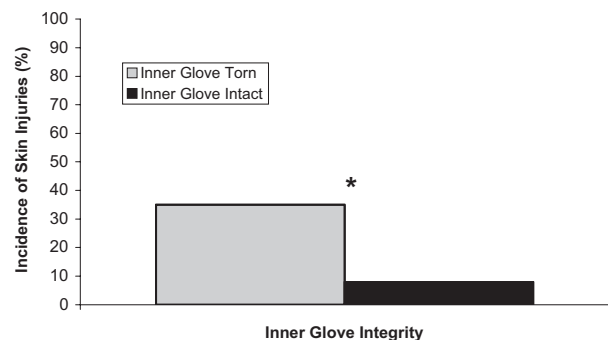


FIGURE 5. Incidence of clinical finger lacerations versus integrity of inner gloves. When the inner glove was torn, there was a significantly increased incidence of clinical finger lacerations (asterisk, $P < .03$).

52% of operations, with bacterial counts and glove tears increasing with the length of surgery, which in our study was correlated with an increasing number of knots thrown.²¹ Furthermore, Palmer and Rickett²² reported that 13% of operative personnel have preoperative skin damage, which significantly increases their risk of infection.

In this prospective study of arthroscopic shoulder surgery, we have shown that intraoperative glove tears occur with a high frequency when arthroscopic knots are tied. We have also documented a higher frequency of subsequent finger lacerations when greater than 3 knots are tied with this high-strength suture material. Al-Maiyah et al.²³ recommended routine glove changing during total hip arthroplasty, which significantly reduced the incidence of glove perforation. This recommendation should be extended to arthroscopic shoulder surgery as well. Seven finger lacerations occurred without the presence of an inner glove tear, suggesting that the injury occurs partly as a result of a pressure or friction phenomenon.

The current literature has estimated that more than 1 in 1,500 surgeons will be infected by HIV during the next 30 years as a result of glove perforation and that surgeons have a significant risk of being in contact with the hepatitis virus during their lifetime.²² Given that the risk of viral transmission is associated with the frequency of exposure to infected body fluids, the type and depth of penetration, and the volume of inoculum,²⁴⁻²⁶ it is prudent to suggest that arthroscopic surgeons may be placed at increased risk of viral or bacterial transmission as a result of glove perforation and subsequent laceration when using solid-core suture material. Despite one case report on the level of HIV found in arthroscopic effluent, we found no reports in the literature regarding the levels of other virulent pathogens such as hepatitis C virus.¹⁶

There are several limitations to this study. We chose to use one type of glove during our study; thus we offer no evidence as to the role of various glove types in preventing perforation and subsequent laceration. Further prospective studies evaluating the effect of different glove types on perforation during surgical knot tying may offer additional recommendations to reduce the spread of infectious material. In addition, the reported rate of fresh finger lacerations was low, because many of the surgeons had an area of callus on their finger from repetitive injury. It may be inferred that the native finger experiences a higher risk of acute lacerations in the absence of a callus. Thus we recommend performing frequent intraoperative glove changes and wearing more durable, less penetrable

gloves to minimize these risks. Our results suggest that a glove change should be performed after every 3 knots. In addition, gloves should be changed anytime the surgeon suspects that he or she has been cut despite the appearance of an intact glove. Finally, the tying surgeons in our study ranged from a fellowship-trained orthopaedic surgeon to a senior resident. However, we believe that this best represents the situation found at most academic orthopaedic institutions.

CONCLUSIONS

Arthroscopic surgeons, despite performing less invasive procedures, remain at significant risk for contamination of the surgical field and infection during surgical knot tying. As shown in this prospective study, intraoperative glove tears and subsequent finger lacerations occur with a high frequency when arthroscopic knots are tied with solid-core suture material. Awareness of this risk may be beneficial to the patient and operating surgeon.

REFERENCES

1. Ippolito G, The Studio Italiano Rischio O. Scalpel injury and HIV infection in a surgeon. The Studio Italiano Rischio Occupazionale da HIV (SIROH). *Lancet* 1996;347:1042.
2. Mujeeb SA, Khatri Y, Khanani R. Frequency of parenteral exposure and seroprevalence of HBV, HCV, and HIV among operation room personnel. *J Hosp Infect* 1998;38:133-137.
3. Stroffolini T, Marzolini A, Palumbo F, et al. Incidence of non-A, non-B and HCV positive hepatitis in healthcare workers in Italy. *J Hosp Infect* 1996;33:131-137.
4. Eckford SD, James M, Jackson SR, Hamer AJ, Browning JJ. Detection of glove puncture and skin contamination during caesarean section. *Br J Obstet Gynaecol* 1997;104:1209-1211.
5. Naver LP, Gottrup F. Incidence of glove perforations in gastrointestinal surgery and the protective effect of double gloves: A prospective, randomised controlled study. *Eur J Surg* 2000;166:293-295.
6. Brough SJ, Hunt TM, Barrie WW. Surgical glove perforations. *Br J Surg* 1988;75:317.
7. Chapman S, Duff P. Frequency of glove perforations and subsequent blood contact in association with selected obstetric surgical procedures. *Am J Obstet Gynecol* 1993;168:1354-1357.
8. Quebbeman EJ, Telford GL, Wadsworth K, Hubbard S, Goodman H, Gottlieb MS. Double gloving. Protecting surgeons from blood contamination in the operating room. *Arch Surg* 1992;127:213-216; discussion 216-217.
9. Jensen SL, Kristensen B, Fabrin K. Double gloving as self protection in abdominal surgery. *Eur J Surg* 1997;163:163-167.
10. Sebold EJ, Jordan LR. Intraoperative glove perforation. A comparative analysis. *Clin Orthop Relat Res* 1993;242-244.
11. Hollaus PH, Lax F, Janakiev D, Wurnig PN, Pridun NS. Glove perforation rate in open lung surgery. *Eur J Cardiothorac Surg* 1999;15:461-464.
12. Macintyre IM, Currie JS, Smith DN, Anderson ID, Cadossi R. Reducing the risk of viral transmission at operation by elec-

- tronic monitoring of the surgeon-patient barrier. *Br J Surg* 1994;81:1076-1078.
13. Nicolai P, Aldam CH, Allen PW. Increased awareness of glove perforation in major joint replacement. A prospective, randomised study of Regent Biogel Reveal gloves. *J Bone Joint Surg Br* 1997;79:371-373.
 14. Salkin JA, Stuchin SA, Kummer FJ, Reininger R. The effectiveness of cut-proof glove liners: Cut and puncture resistance, dexterity, and sensibility. *Orthopedics* 1995;18:1067-1071.
 15. Cannon WD Jr, Vittori JM. AIDS and arthroscopic surgery. *Arthroscopy* 1992;8:279-286.
 16. Matava MJ, Horgan M. Serial quantification of the human immunodeficiency virus in an arthroscopic effluent. *Arthroscopy* 1997;13:739-742.
 17. Stampfer JF, Salazar JA, Trujillo AG, Harris T. Examination of several instruments for the electrical detection of holes in latex gloves during use. *J Clin Eng* 1996;21:212-225.
 18. Sohn RL, Murray MT, Franko A, Hwang PK, Dulchavsky SA, Grimm MJ. Detection of surgical glove integrity. *Am Surg* 2000;66:302-306.
 19. Maffulli N, Capasso G, Testa V. Glove perforation in elective orthopedic surgery. *Acta Orthop Scand* 1989;60:565-566.
 20. Eckersley JR, Williamson DM. Glove punctures in an orthopaedic trauma unit. *Injury* 1990;21:177-178.
 21. Bukhari SS, Harrison RA, Sanderson PJ. Contamination of surgeons' glove fingertips during surgical operations. *J Hosp Infect* 1993;24:117-121.
 22. Palmer JD, Rickett JW. The mechanisms and risks of surgical glove perforation. *J Hosp Infect* 1992;22:279-286.
 23. Al-Maiyah M, Bajwa A, Mackenney P, et al. Glove perforation and contamination in primary total hip arthroplasty. *J Bone Joint Surg Br* 2005;87:556-559.
 24. Mast ST, Woolwine JD, Gerberding JL. Efficacy of gloves in reducing blood volumes transferred during simulated needlestick injury. *J Infect Dis* 1993;168:1589-1592.
 25. De Carli G, Puro V, Ippolito G. Risk of hepatitis C virus transmission following percutaneous exposure in healthcare workers. *Infection* 2003;31:22-27 (suppl 2).
 26. De Carli G, Puro V, Scognamiglio P, Ippolito G. Infection with hepatitis C virus transmitted by accidental needlesticks. *Clin Infect Dis* 2003;37:1718-1719; discussion 1719.