

Primary Total Hip Arthroplasty With a Flanged, Cemented All-Polyethylene Acetabular Component

Evaluation at a Minimum of 20 Years

Craig J. Della Valle, MD,* Kevin Kaplan, BS,† Adele Jazrawi, BS,† Shazia Ahmed, BA,† and William L. Jaffe, MD†

Abstract: One hundred twenty-three consecutive primary total hip arthroplasties in 107 patients were performed with the insertion of a cemented, all polyethylene, flanged acetabular component. At a minimum of 20 years, 66 patients had died (75 hips) and 8 patients (8 hips) were lost to follow-up evaluation, leaving 40 hips in 33 patients. At a mean of 21.1 years, 2 cups had been revised for aseptic loosening, one well-fixed cup was revised at the time of femoral component revision, and 4 additional cups had definite evidence of radiographic loosening. Survivorship analysis revealed a 77.3% survivorship for the component at 21 years, with revision or definite loosening as an endpoint (95% confidence interval, 67.8%–86.8%). **Key words:** total hip arthroplasty, cemented, acetabular component, outcome.

© 2004 Elsevier Inc. All rights reserved.

Total hip arthroplasty reliably relieves pain and improves function. The original surgical technique included use of an all-polyethylene acetabular component inserted with cement, as well as a cemented femoral component [1]. Higher rates of radiographic and clinical loosening, particularly in younger patients, have been reported for cemented, all-polyethylene acetabular components [2–6], and many surgeons have moved toward cementless acetabular fixation. Few studies, however, document the results of a cemented, all-polyethylene component at more than 20 years [7–12]. Collection of such long-term data is imperative for making in-

formed decisions regarding implant selection. The purpose of this study was to analyze the results of primary total hip arthroplasty with the use of a flanged, cemented, all-polyethylene acetabular component at a follow-up of more than 20 years.

Materials and Methods

One hundred twenty-three consecutive primary total hip arthroplasties in 107 patients were performed between November of 1977 and August of 1981 by a single surgeon using a cemented, all-polyethylene, flanged acetabular component (Charles F. Thackray, Leeds, UK). A 22-mm femoral head was used in all cases. The surgical approach was transtrochanteric, and prophylactic antibiotics were administered before skin incision and for 48 hours postoperatively. Although not the focus of this study, femoral components used included 80 Charnley femoral stems (Charles F. Thackray), 23 HS1 stems (Osteonics, Allendale, NJ), and 20 HS2 stems (Osteonics).

*From the *Department of Orthopaedic Surgery, Rush-Presbyterian-St. Luke's Medical Center, Chicago, Illinois, and the †Department of Orthopaedic Surgery, NYU-Hospital for Joint Diseases, New York, New York.*

Submitted February 28, 2003; accepted August 22, 2003.

No benefits or funds were received in support of this study.

Reprint requests: Craig J. Della Valle, MD, 1725 West Harrison, Suite 1063, Chicago, IL 60612.

© 2004 Elsevier Inc. All rights reserved.

0883-5403/04/1901-0005\$30.00/0

doi:10.1016/j.arth.2003.08.002

The original cohort consisted of 68 women (73 hips) and 39 men (50 hips) with a mean age of 60.2 years at surgery (range, 23–87 years). The diagnosis that led to the total hip arthroplasty was osteoarthritis in 92 hips (75%), osteonecrosis in 11 hips, developmental dysplasia in 5 hips, rheumatoid arthritis in 3 hips, post-traumatic arthritis in 3 hips, Paget's disease in 2 hips, slipped capital femoral epiphysis in 2 hips, and ankylosis spondylitis, poliomyelitis, and previous septic arthritis in one hip each. Of the 16 patients who underwent bilateral total hip arthroplasty, 12 were performed as part of a simultaneous bilateral procedure, and 2 were performed within the same hospitalization.

Patients were evaluated preoperatively and postoperatively using Merle d'Aubigne and Postel [13] pain and walking scores, as modified by Charnley [1]. Serial radiographs of the pelvis and ipsilateral hip were reviewed by authors who were not involved in the original surgical procedure and compared with radiographs obtained 6 weeks postoperatively to determine if evidence of component migration [14] or demarcation was present in any of the 3 zones as described by De Lee and Charnley [15]. Acetabular components were considered to have definite radiographic evidence of loosening if evidence of migration [14,16], cement mantle fracture, or a 100% radiolucent line in all 3 acetabular zones was seen. Acetabular loosening was considered probable if a radiolucent line around 50% to 99% of the component was seen [16].

Kaplan-Meier survivorship analysis [17] was performed with revision for aseptic loosening and radiographic evidence of loosening or revision for aseptic loosening as end-points. All clinical and radiographic data available from patients who were known to have died or who were lost to follow-up before 20 years was used for survivorship analysis. Statistical analysis was performed using a 2-tailed Student's *t*-test.

Results

At a minimum of 20 years postoperatively, 66 patients had died (75 hips), and 8 patients (8 hips) were lost to follow-up. This left 40 hips in 33 patients for study. Thirty patients (35 hips) returned for radiographic and clinical evaluation, and 3 patients (5 hips) answered a telephone questionnaire but refused radiographic evaluation. Clinical evaluation averaged 21.1 years (range, 20–23.5 years) and radiographic evaluation averaged 21.2 years (range, 20–23.5 years). Of the 8 patients lost

to follow-up evaluation, 6 had been followed up for a mean of 10.1 years postoperatively but could not be located for follow-up evaluation at 20 years. The remaining 2 had less than 2 years of follow-up evaluation. The mean age at surgery of the patients who survived more than 20 years was 53 years (range, 23–83 years), and this subset consisted of 22 women (55%).

Pain and walking scores for the patients whose hips had not been revised and had survived for more than 20 years improved from a mean of 6.5 preoperatively (range, 3–10) to 10.9 (range, 8–12) at the most recent evaluation ($P < .001$). Two of the 40 acetabular components (5%) required revision for aseptic loosening (at 13.5 and 21.3 years postoperatively) and one stable acetabular component was removed at the time of femoral revision surgery (23.5 years postoperatively). Of the 32 unrevised hips with radiographic follow-up evaluation of more than 20 years, an additional 4 patients had definite evidence of loosening of the acetabular component. No acetabular component was found to be probably loose (Figs. 1, 2). Thus, 6 of the 40 acetabular components (15%) in patients who had survived for more than 20 years had either been revised for aseptic loosening or had radiographic evidence of aseptic loosening.

When only patients with clinical and radiographic evaluation are considered, the failure rate is 6 of 35 acetabular components (17%). One patient who died before 20 years was noted to have definite radiographic evidence of loosening at 18 years postoperatively, and one patient had a possibly loose component at 9.5 years postoperatively but died at 12 years postoperatively. No other patient who died before 20 years was known to have had revision surgery or radiographic evidence of loosening. Survivorship at 21 years was 92.3% (95% confidence interval [CI], 84.9%–99.7%) with revision for aseptic loosening as an endpoint and 77.3% (95% CI, 67.8%–86.8%) with revision for aseptic loosening or radiographic evidence of loosening as a second endpoint.

Discussion

Previous studies that examined the results of total hip arthroplasty performed with an acetabular component inserted with cement, at a follow-up time of 20 to 25 years, have shown revision rates for aseptic loosening of 10% to 19%, with an additional 12% to 25% of the acetabular components showing signs of loosening in patient cohorts of 59 to 85 hips [8–10,12]. Berry et al. [11] studied 2,000 con-

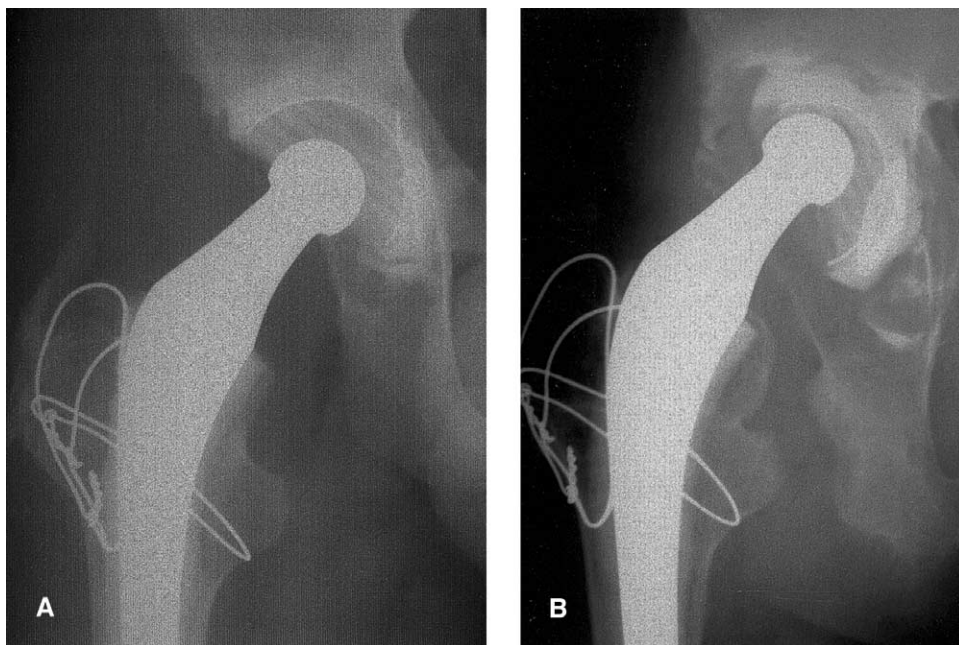


Fig. 1. (A) Immediate post-operative and (B) follow-up radiograph taken at 20 years and 3 months postoperatively. The acetabular component is loose with evidence of migration of more than 5 mm.

secutive primary total hip arthroplasties performed with cement followed up for more than 25 years and found that survivorship of the acetabular component was 87% at 25 years. However, a radiographic analysis was not performed in this study, and thus the true rate of failure may have been underestimated.

The acetabular component used in this study performed well with a relatively low rate of revision (5%) and loosening (10%) seen in this cohort of 40 patients followed up for more than 20 years, although our study did document a higher rate of radiographic than clinical failure, as have previous studies [8–10,12]. All of the procedures in this

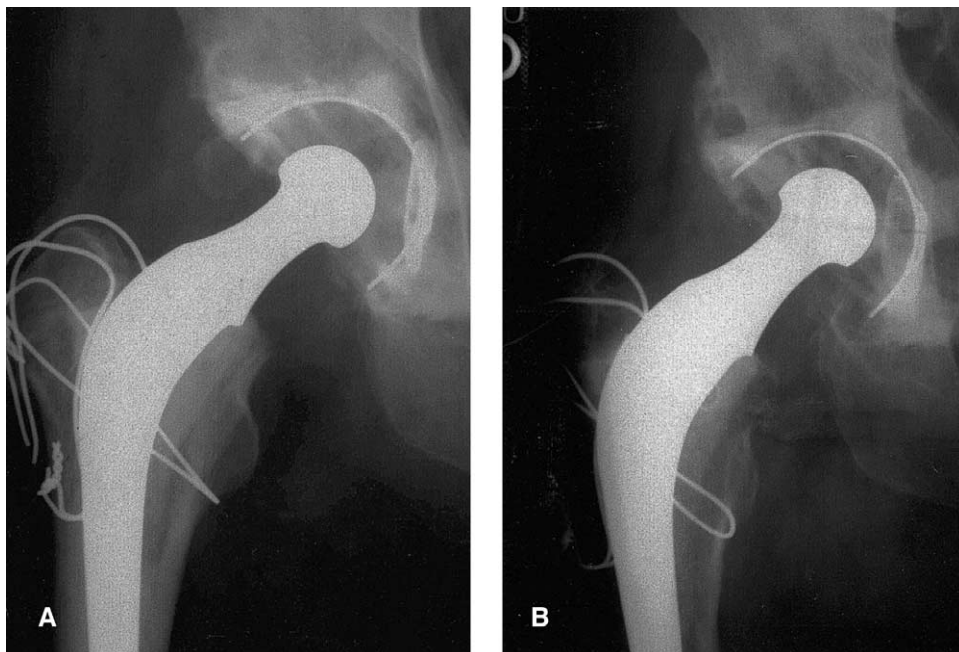


Fig. 2. (A) Immediate post-operative and (B) follow-up radiograph taken at 22 years and 7 months postoperatively. The acetabular component is well fixed but does show evidence of polyethylene wear. An osteolytic lesion is present in zone 1.

cohort were performed by a single surgeon, who was trained by the originator of the operation. Thus, surgical technique may have played a factor in the results observed.

That all 4 of the patients with definite evidence of radiographic loosening were asymptomatic with pain and walking scores that ranged from 10 to 12 was interesting. Three of these patients were seen to have more than 5 mm of component migration. This finding confirms the need to radiographically monitor all patients who have undergone total hip arthroplasty on an annual or biannual basis to identify component loosening before significant damage to pelvic bone stock occurs that may compromise the results of subsequent revision surgery.

The major limitation of this study is the lack of complete radiographic and clinical follow-up data on patients who had died before a minimum of 20 years. The absence of this evidence is reflected in the relatively wide confidence intervals determined for the survivorship data. Patients surviving for more than 20 years were younger than those who died before 20 years, however (mean age of 56 years compared with a mean age of 64 years at the time of surgery for those who died before 20 years), and would be expected to have improved results given the older age and decreased time of prosthetic use *in vivo* compared with the patients who survived and were followed up for more than 20 years.

In conclusion, the use of a cemented, all-polyethylene acetabular component was associated with a low rate of repeat surgery and revision in this patient cohort, with a higher but still relatively low rate of radiographic loosening. Additional studies that document the long-term performance of cementless acetabular reconstruction are needed to determine if this method of acetabular reconstruction will outperform the results of insertion of the acetabular component with cement.

References

1. Charnley J: Low friction arthroplasty of the hip. Theory and practice. New York, Springer-Verlag, 1979
2. Kavanagh BF, Dewitz MA, Ilstrup DM, et al: Charnley total hip arthroplasty with cement: fifteen-year results. *J Bone Joint Surg Am* 71:1496, 1989
3. Madey SM, Callaghan JJ, Olejniczak JP, et al: Charnley total hip arthroplasty with use of improved techniques of cementing: the results after a minimum of fifteen years of follow-up. *J Bone Joint Surg Am* 79:53, 1997
4. Mulroy WF, Estok DM, Harris WH: Total hip arthroplasty with use of so-called second-generation cementing techniques: a fifteen-year-average follow-up study. *J Bone Joint Surg Am* 77:1845, 1995
5. Smith SW, Estok DM 2nd, Harris WH: Total hip arthroplasty with use of second-generation cementing techniques: an eighteen-year-average follow-up study. *J Bone Joint Surg Am* 80:1632, 1998
6. Wroblewski BM: 15-21-year results of the Charnley low-friction arthroplasty. *Clin Orthop*: 30, 1986
7. Kavanagh BF, Wallrichs S, Dewitz M, et al: Charnley low-friction arthroplasty of the hip: twenty-year results with cement. *J Arthroplasty* 9:229, 1994
8. Schulte KR, Callaghan JJ, Kelley SS, Johnston RC: The outcome of Charnley total hip arthroplasty with cement after a minimum twenty-year follow-up: the results of one surgeon. *J Bone Joint Surg Am* 75:961, 1993
9. Callaghan JJ, Albright JC, Goetz DD, et al: Charnley total hip arthroplasty with cement: minimum twenty-five-year follow-up. *J Bone Joint Surg Am* 82:487, 2000
10. Callaghan JJ, Forest EE, Olejniczak JP, et al: Charnley total hip arthroplasty in patients less than fifty years old: a twenty to twenty-five-year follow-up note. *J Bone Joint Surg Am* 80:704, 1998
11. Berry DJ, Harmsen WS, Cabanela ME, Morrey BF: Twenty-five-year survivorship of two thousand consecutive primary Charnley total hip replacements: factors affecting survivorship of acetabular and femoral components. *J Bone Joint Surg Am* 84:171, 2002
12. Klapach AS, Callaghan JJ, Goetz DD, et al: Charnley total hip arthroplasty with use of improved cementing techniques: a minimum twenty-year follow-up study. *J Bone Joint Surg Am* 83:1840, 2001
13. Merle d'Aubigne R, Postel M: Functional results of hip arthroplasty with acrylic prosthesis. *J Bone Joint Surg Am* 36:451, 1954
14. Massin P, Schmidt L, Engh CA: Evaluation of cementless acetabular component migration: an experimental study. *J Arthroplasty* 4:245, 1989
15. DeLee JG, Charnley J: Radiological demarcation of cemented sockets in total hip replacement. *Clin Orthop* 121:20, 1976
16. Hodgkinson JP, Shelley P, Wroblewski BM: The correlation between the roentgenographic appearance and operative findings at the bone-cement junction of the socket in Charnley low friction arthroplasties. *Clin Orthop* 228:105, 1988
17. Kaplan EL, Meier P: Nonparametric estimation from incomplete observations. *J Am Statist Assn* 53:457, 1958